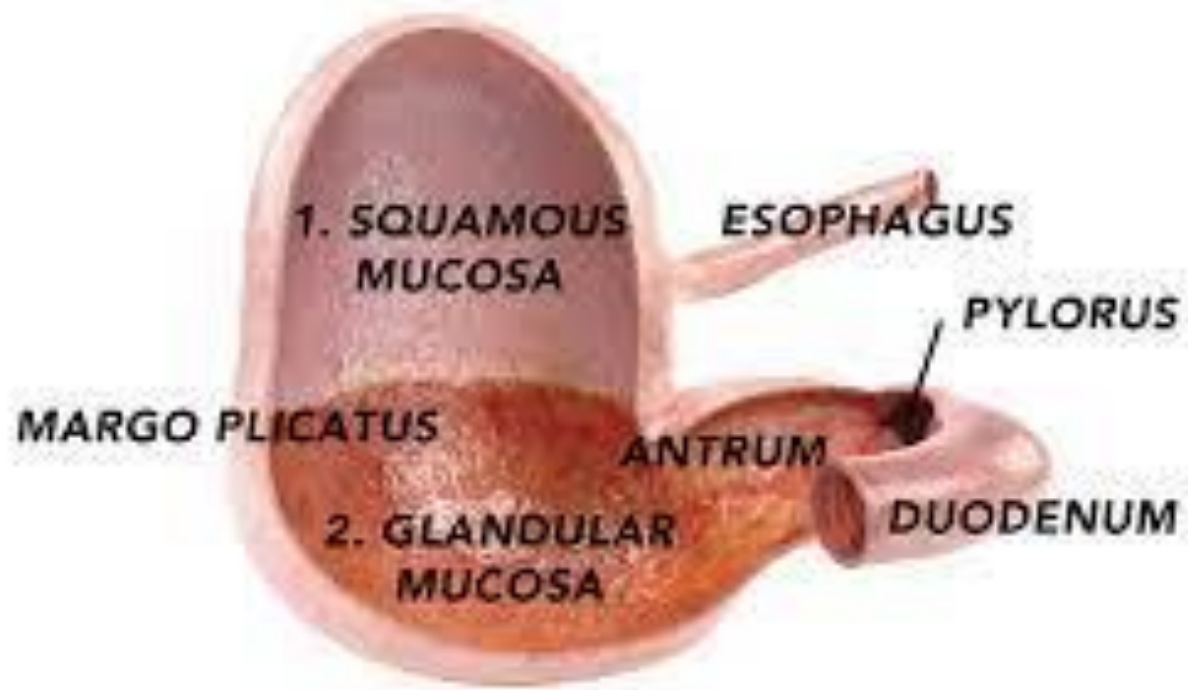


Equine Gastric Ulcers

Corey Paradine DVM



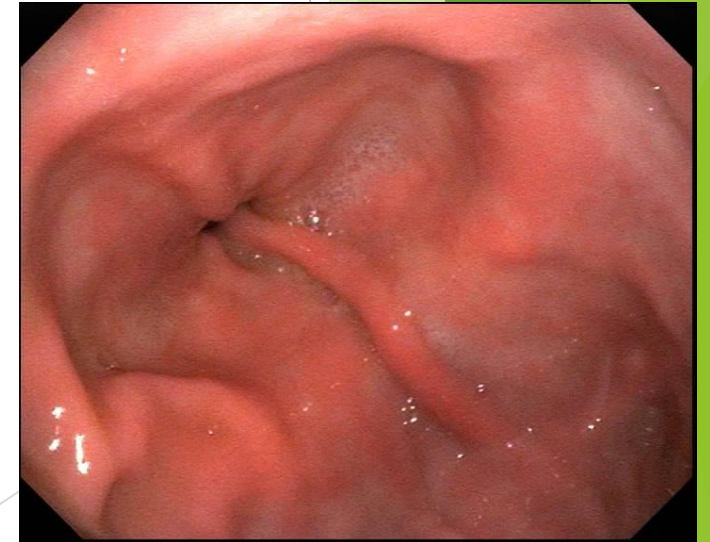
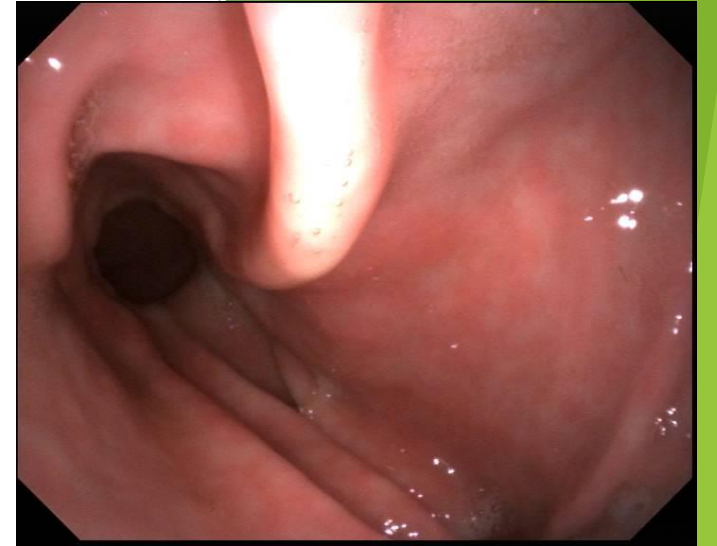
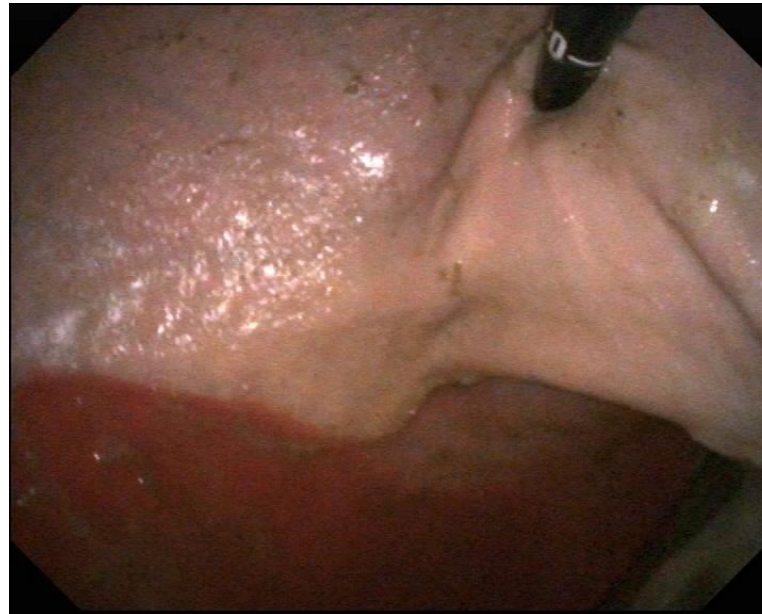
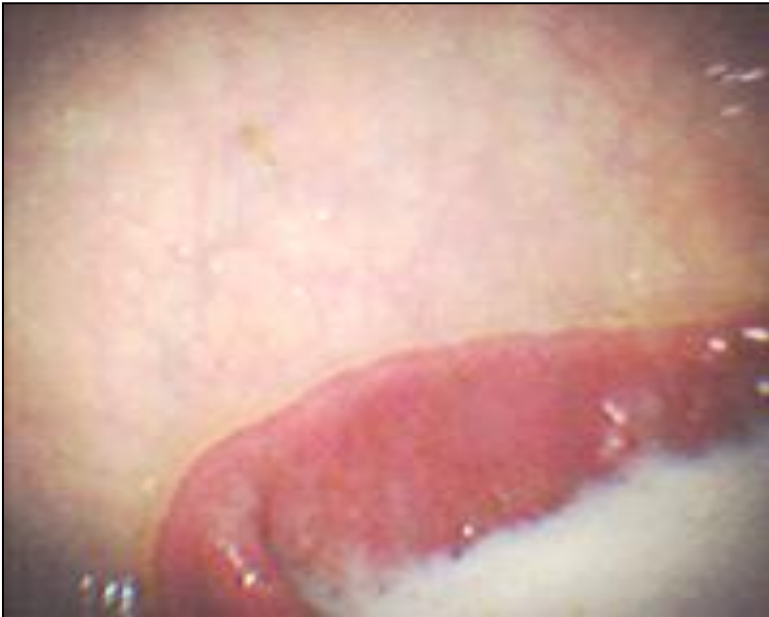
Anatomy



NOTE: Image represents an empty, air-filled stomach as observed during gastroscopy.

Anatomy

Normal Stomach



What causes gastric ulcers?

- ▶ Management
 - ▶ Stalling/limited turnout
 - ▶ Feeding meals rather than continuous grazing
- ▶ NSAIDs
 - ▶ Bute, Banamine, Equioxx
- ▶ Domestic horses have added stress from training, traveling, herd changes, the wind blew differently, etc etc
- ▶ ???
 - ▶ Lots of research still being done
 - ▶ -differences between non-glandular ulcer disease and glandular/pyloric ulcer disease



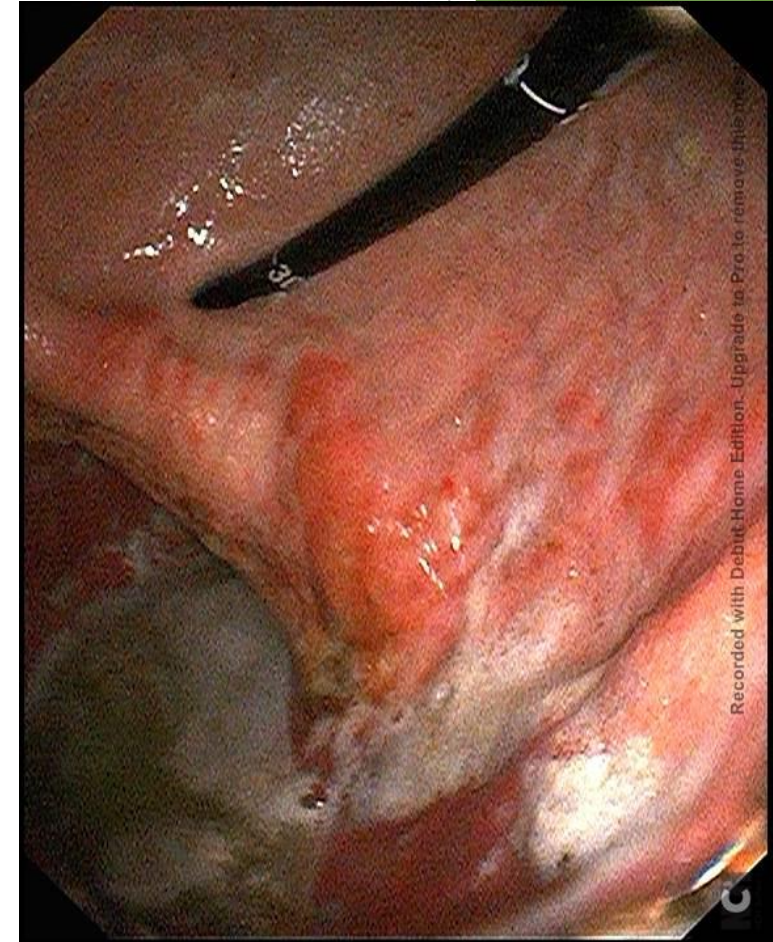What are the symptoms of gastric ulcers?

- Weight loss
 - Reduced appetite
 - Poor hair coat
 - Recurrent colic
 - **Attitude changes**
 - **Poor performance**
- **NOT USUALLY SPECIFIC!**



Diagnosing gastric ulcers

- ▶ **Gastroscopy!!**
- ▶ Sucralfate trial
 - ▶ Acts as a band-aid over lesions
 - ▶ Horses usually respond positively after a few days
- ▶ Fecal blood test??
 - ▶ Not shown to be reliable
- ▶ NOT by symptoms alone!

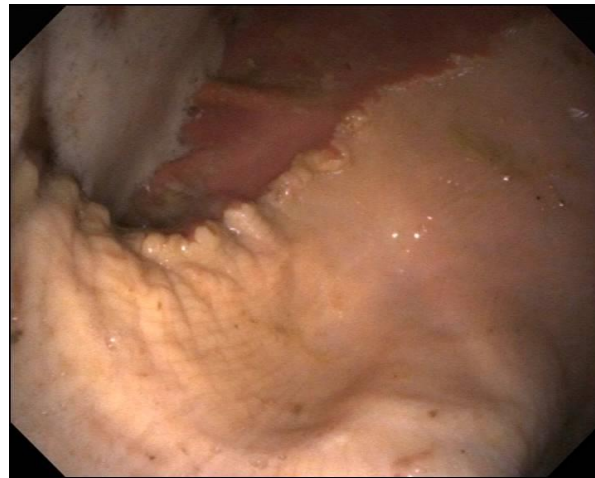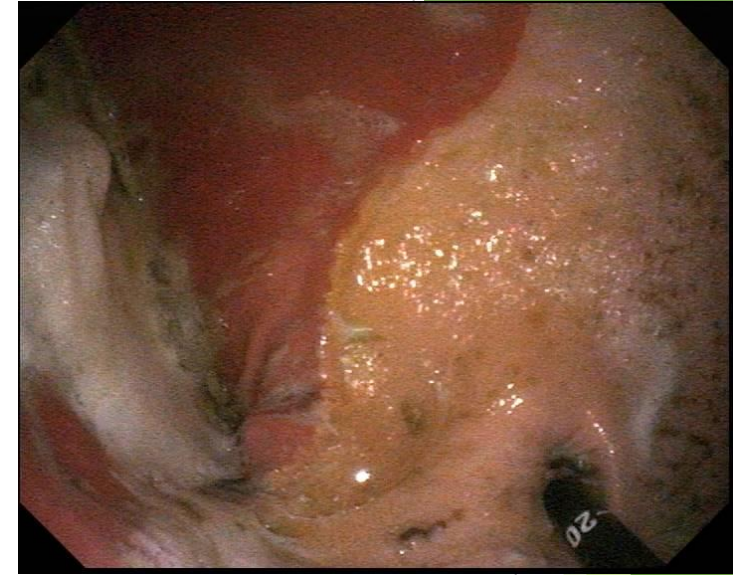


What are gastric ulcers?

- ▶ Equine Squamous Gastric Disease

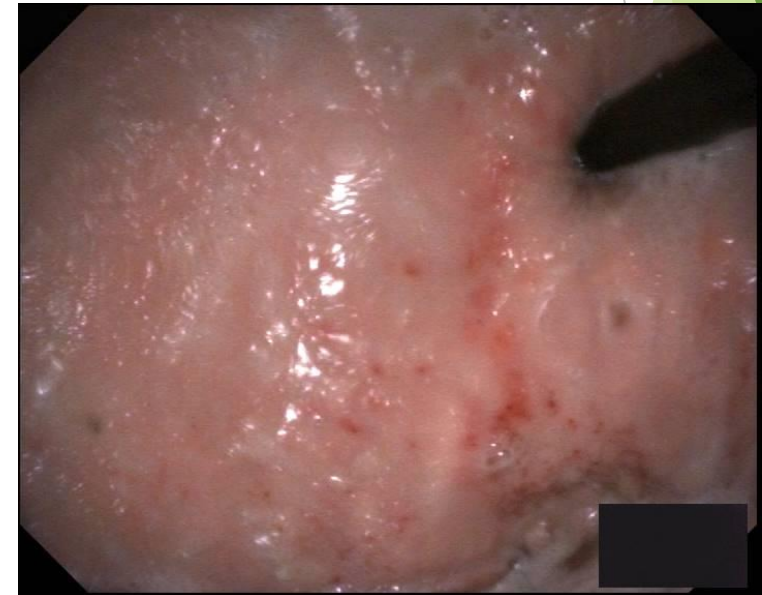
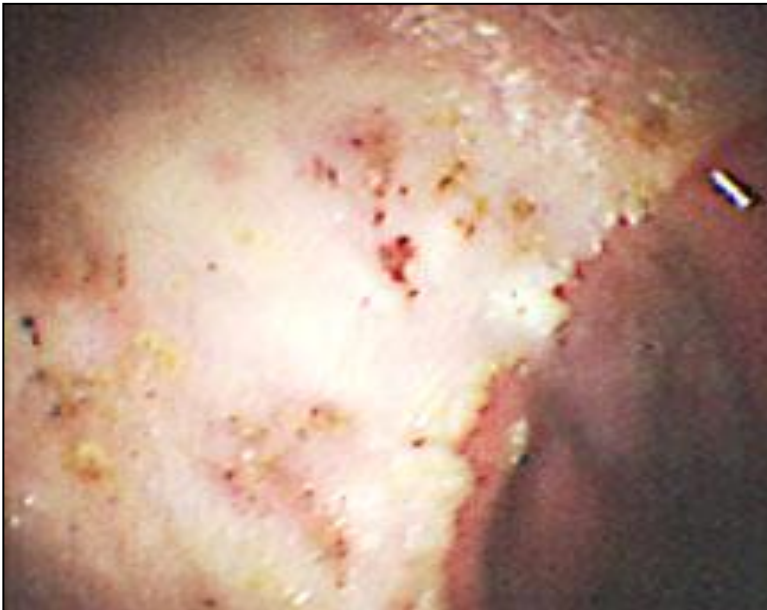
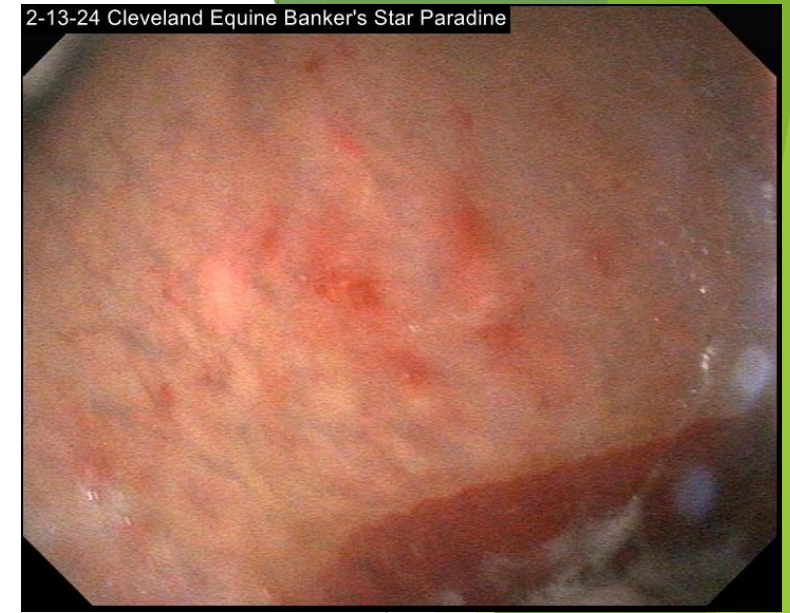- ▶ Grade 1 lesion

- ▶ Mucosa is intact, but there are areas of hyperkeratosis or gastritis



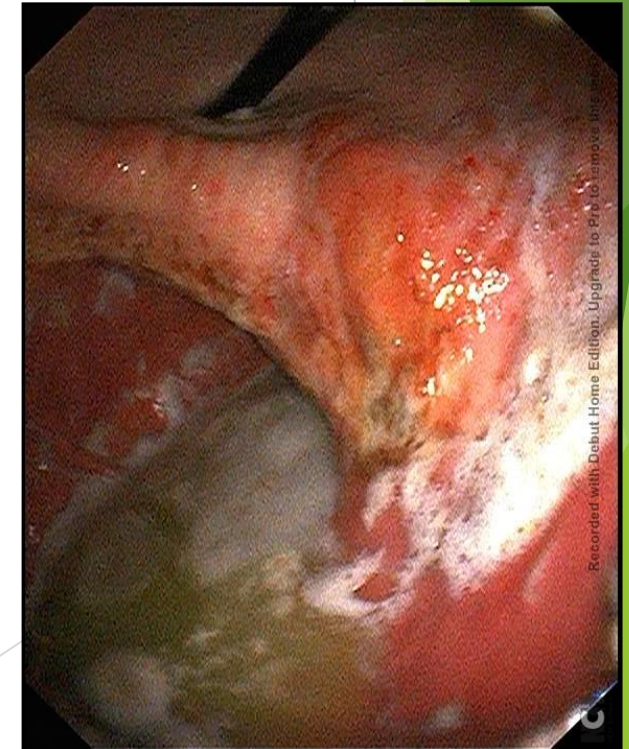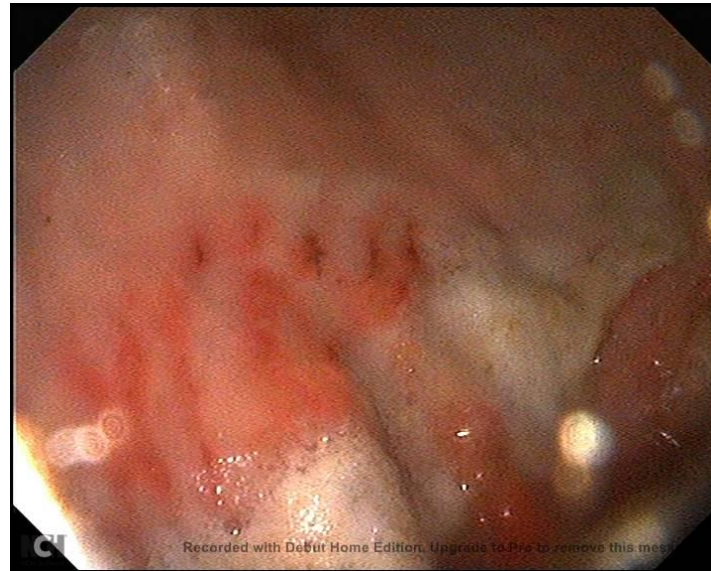
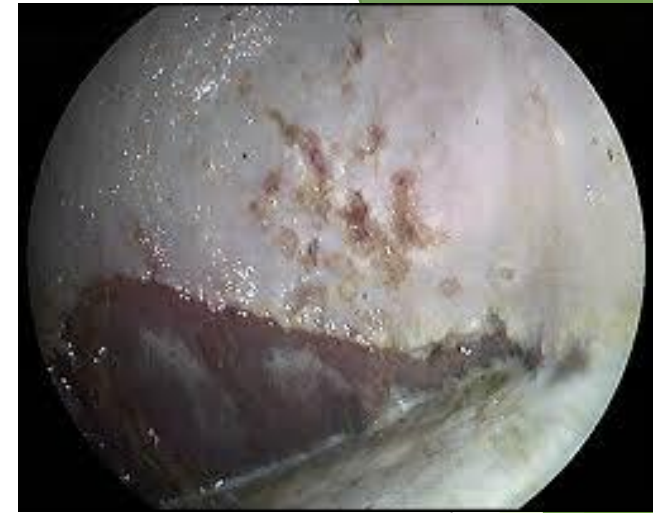What are gastric ulcers?

- ▶ Equine Squamous Gastric Disease
 - ▶ Grade 2 Lesion
 - ▶ Small, single or multi-focal lesions; superficial



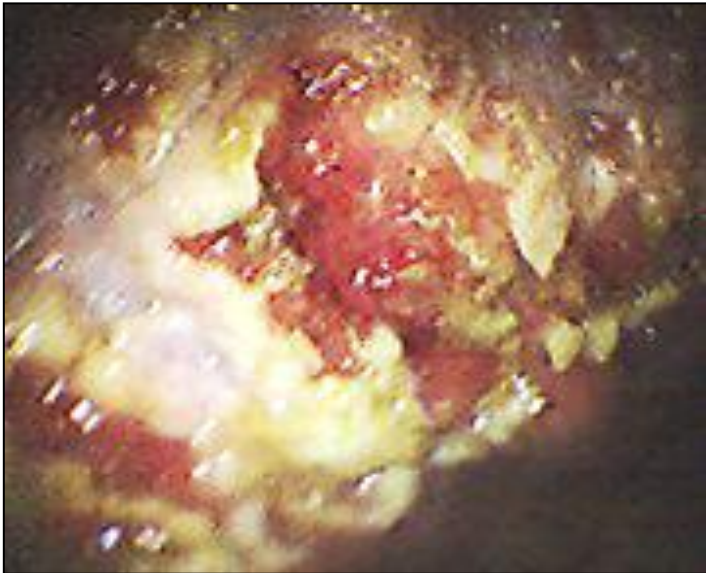
What are gastric ulcers?

- ▶ Equine Squamous Gastric Disease
- ▶ Grade 3 Lesion (Moderate Ulceration)
 - ▶ Large single or extensive superficial lesions



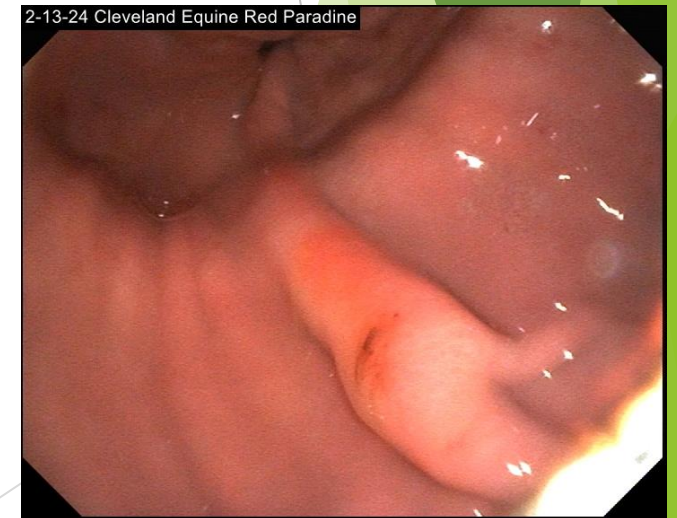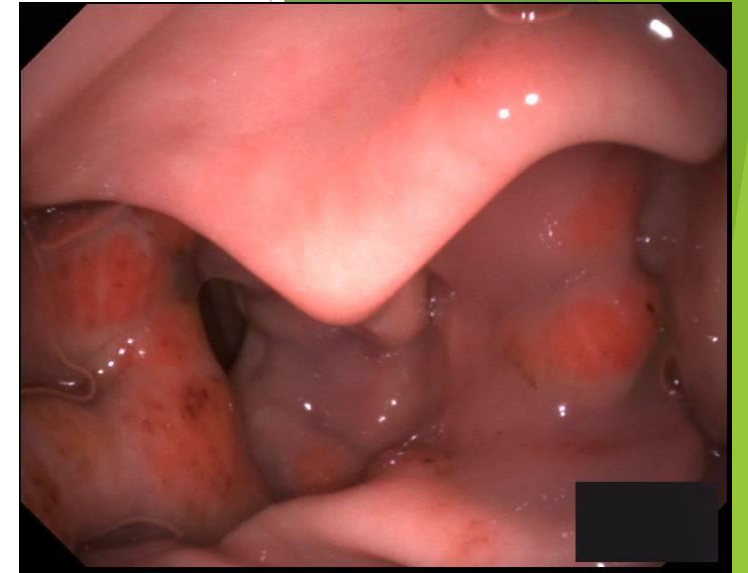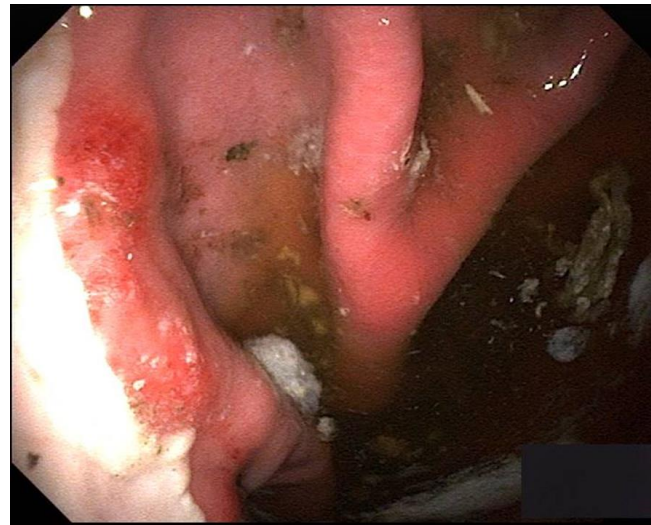
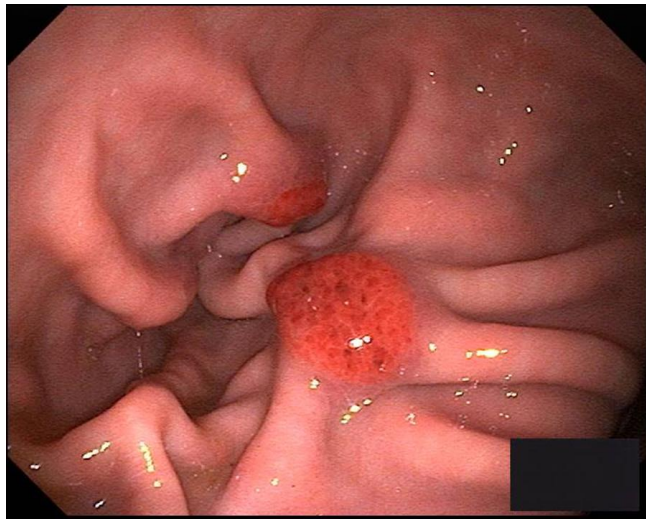
What are gastric ulcers?

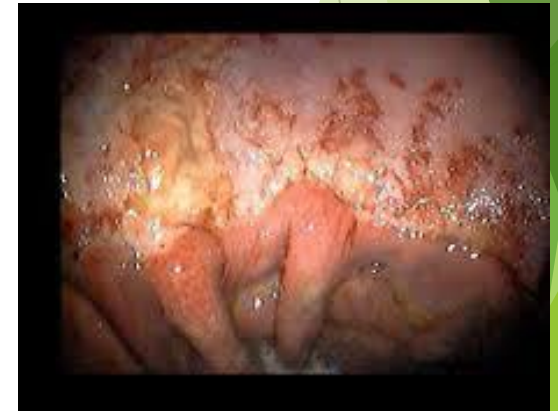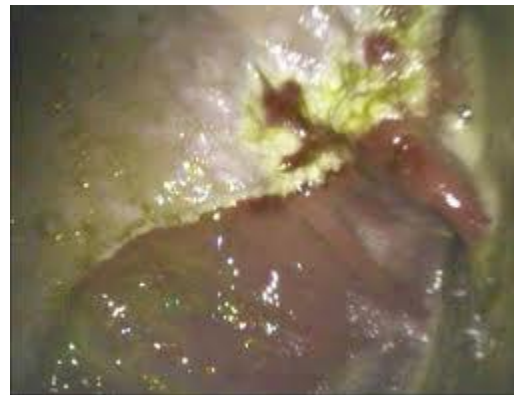
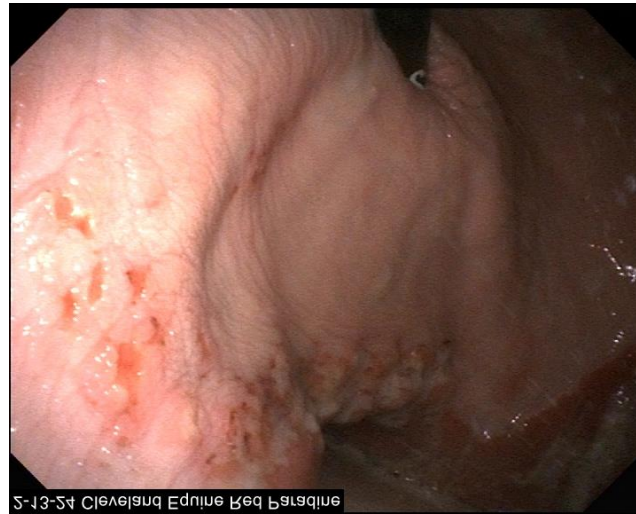
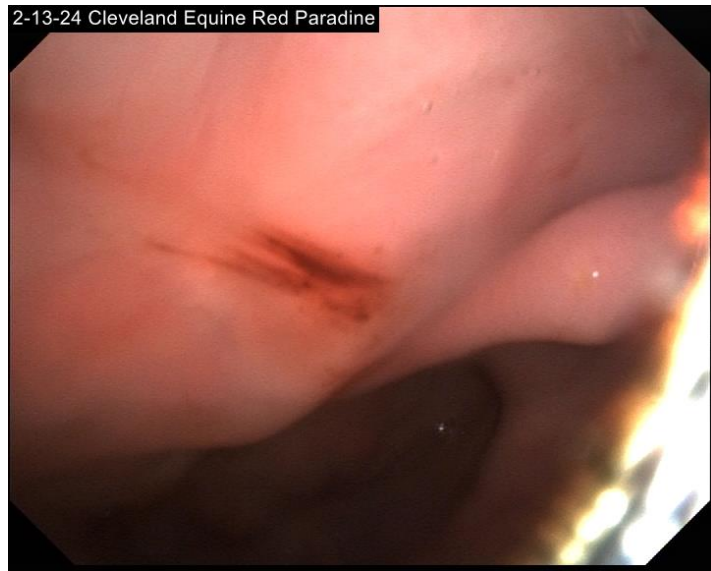
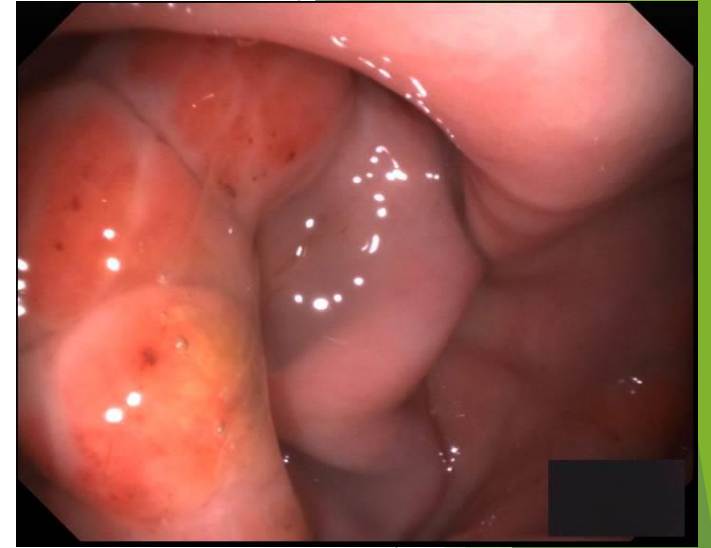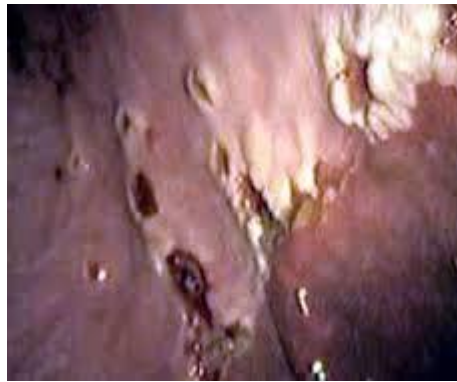
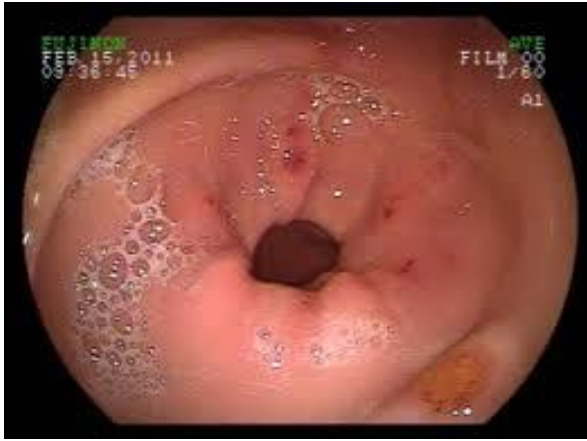- ▶ Equine Squamous Gastric Disease
- ▶ Grade 4 Lesion (Severe Ulceration)
 - ▶ Extensive lesions with areas of apparent deep ulceration



What are gastric ulcers?

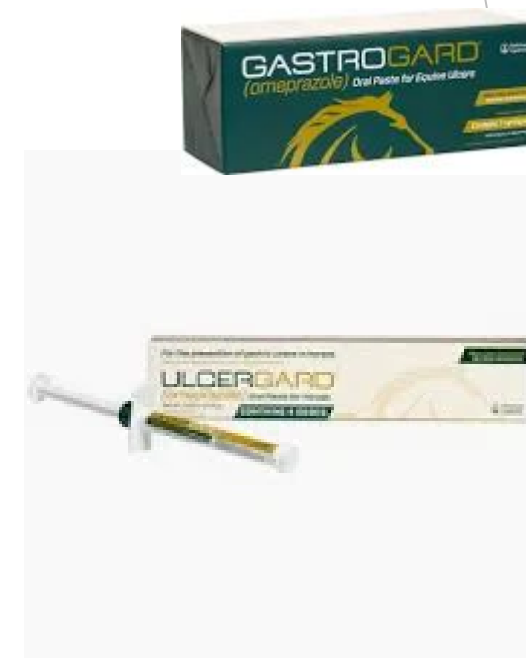- ▶ Equine Glandular Gastric Disease/Pyloric lesions
 - ▶ Not usually graded, described instead
 - ▶ Fibrinosuppurative
 - ▶ Erythematous, hemorrhagic
 - ▶ Raised, flat, or depressed





Treatment of gastric ulcers

- ▶ Omeprazole
 - ▶ Only FDA approved treatment - Gastrogard
 - ▶ Only FDA approved drug for prevention - Ulcergard
- ▶ Sucralfate
- ▶ Misoprostol
 - ▶ Primarily used for glandular/pyloric ulcers
- ▶ H2 antagonists (cimetidine, ranitidine, famotidine)
 - ▶ Used occasionally but not as effective as Ulcergard
- ▶ Compounds?
 - ▶ Not worthwhile; omeprazole needs an appropriate carrier agent to get through stomach acid into the small intestine to be absorbed
- ▶ Antibiotics?
 - ▶ Bacteria not shown to be a causative agent in equine gastric ulcer disease



Feed and management

- ▶ Alfalfa
- ▶ Continuous hay
- ▶ Low-starch grains
- ▶ Oil
- ▶ Turnout
 - ▶ As much as possible, with friends
- ▶ Stress management
- ▶ Number of work days
 - ▶ No more than 5 days/week, split up, for glandular ulcers



Ulcer Supplements

- ▶ Soooooo many
- ▶ Ones I routinely recommend
 - ▶ Protek GI
 - ▶ Purina Outlast
 - ▶ Relyne
- ▶ Platinum Performance GI
- ▶ Succeed



Thank you to BI for their
sponsorship and support



Thanks!! Questions?



CLEVELAND
EQUINE CLINIC

